
PRESENTING CLINICAL SIGNS

DATE History: Grade IV/VI left-sided murmur. Asymptomatic. Started on pimobendan 1.25 mg BID.

ECHOCARDIOGRAPHIC FINDINGS

1/31/23 2D, M-mode, and Doppler study.

PERFORMED BY:

Dr. Meredith Swart

There is moderate to severe left atrial dilation. The mitral valve leaflets are thickened and exhibit systolic prolapse. A moderate to severe jet of eccentric mitral regurgitation is present. There is moderate to severe left ventricular dilation. Left ventricular systolic function is hyperdynamic. The aorta and aortic valve are normal. Right atrial and right ventricular dimensions are normal.

INTERPRETED BY

Keith Blass, DVM,
MS, DACVIM
(Cardiology)

The tricuspid valve is normal. The pulmonary artery and pulmonic valve are normal. No shunting lesions are visualized. No pericardial effusion or cardiac masses are seen.

LA - 35.7 mm
LVIDd - 35.0 mm
LVIDs - 15.3 mm
FS - 56.2%

PATIENT

Falkora McCrossan

RA - 19.2 mm
LVOT - 1.42 m/s
RVOT - 0.89 m/s

ASSESSMENT/RECOMMENDATIONS
SPECIES

Canine

Degenerative mitral valve disease

Falkora's echocardiogram demonstrates moderate to severe regurgitation of blood across his mitral valve resulting from degenerative valve disease. Secondary to the regurgitation, Falkora has moderate to severe dilation of both his left atrium and left ventricle, though his left ventricular systolic function is well-preserved. While Falkora is still asymptomatic, the severity of his disease indicates that he is at high risk for the development of clinical signs, such as coughing, exercise intolerance, syncope, and labored breathing, therefore, careful monitoring for these signs is recommended.

BREED

Yorkie

SEX

Continued use of pimobendan is warranted based on this exam. No additional therapy has been proven to be beneficial at this stage of Falkora's mitral valve disease.

MN

A recheck echocardiogram is recommended in 6 months to monitor for disease progression. Thoracic radiographs are recommended if Falkora experiences respiratory clinical signs.

AGE

11 y

WEIGHT

11.3 lb

HOSPITAL NAME

Swart Veterinary
Imaging

REFERRING VET

Dr. Swart



DATE

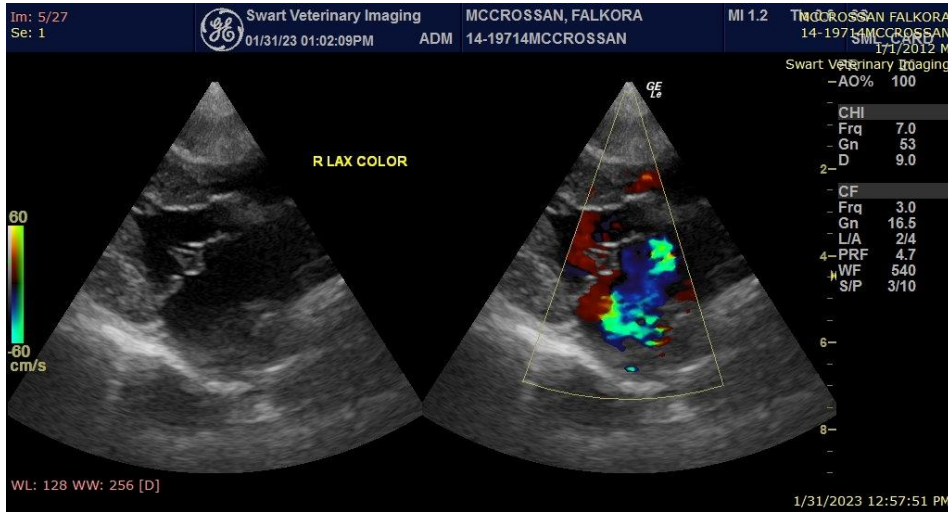
1/31/23

PERFORMED BY:

Dr. Meredith Swart

INTERPRETED BY

Keith Blass, DVM,
MS, DACVIM
(Cardiology)



PATIENT

Falkora McCrossan

The information and recommendations provided are based on the images presented by the referring veterinarian. No evaluation can be communicated regarding pathology that was not visible in the image/video clips provided.

SPECIES

Canine

Keith Blass, DVM, MS, DACVIM (Cardiology)
KeithBlass@gmail.com

BREED

631-804-5754

Yorkie

SEX

MN

AGE

11 y

WEIGHT

11.3 lb

HOSPITAL NAME

Swart Veterinary
Imaging

REFERRING VET

Dr. Swart

Thank you for this referral. If the clinical or image interpretation does not parallel your findings or if I can be of any further assistance please contact me.